

Operative Vaginal Deliveries in Contemporary Obstetric Practice

Sunday E. Adaji¹ and Charles A. Ameh²

¹*Ahmadu Bello University and Ahmadu Bello University Teaching Hospital, Zaria,*

²*Liverpool School of Tropical Medicine, Pembroke Place, Liverpool,*

¹*Nigeria*

²*United Kingdom*

1. Introduction

The expectation of every pregnant woman is to undergo a spontaneous vaginal delivery with minimal or no resort to operative procedures at the end of pregnancy. For the majority of women this expectation becomes a reality. For some however, assistance is required either in the form of caesarean sections or operative vaginal procedures in order to avert adverse maternal and fetal outcomes. Assisting laboring women to deliver vaginally using specialized instruments is a practice that dates back several centuries. Forceps and ventouse are the most popular of the operative vaginal procedures with comprehensive documentation of their development and use in the lay and medical media. Procedures like symphysiotomy and destructive operations to remove a dead fetus are probably now materials for the waste bins of medical history. However some still argue for a place for them in modern obstetric practices especially in low income countries where the indications for their use may still be found (Maharaj and Moodley, 2002).

Instrumental vaginal delivery is a key element of essential obstetric care, scaling up its use in resource poor countries through training and supply of appropriate equipment is likely to contribute significantly to reduced maternal and newborn morbidity/mortality (Ameh and Weeks, 2009).

2. The obstetrical forceps

‘Use only on the most urgent occasions

‘Head on the perineum for 6 hours

‘If the head advances, no matter how slowly, no interference unless the child be dead

‘Use the forceps sparingly -

‘Where they save one they murder many’

~A summary of the guidelines for the use forceps in Smellie’s time

The obstetrical forceps is probably the earliest instrument designed to assist vaginal delivery. Behind its design, invention and evolution lies a florid and interesting history

with ancient Egyptian, Greek, Roman, and Persian texts containing references to the use of forceps to deliver women in cases of intrauterine fetal deaths. The refugee family of William Chamberlain, who facing religious persecution in their home country of France, migrated to London in the 16th Century is widely credited with the development of the obstetrical forceps as is known today. This family takes credit for the design, invention and use of obstetrical forceps to deliver women with obstructed labour for about three generations (Dunn, 1999). The instruments and their use were a well-kept family secret, only revealed nearly 200 years after their invention! Obstetrical forceps have undergone several modifications over time. It is estimated that there may well be over 700 different types of obstetrical forceps in existence, not counting those that did not make it beyond the design stage. The types vary by designer, intended objective of using it, material, place and sometimes the ingenuity of the inventor. Forceps are designed to aid the delivery of the fetal head by the application of traction. To effect a delivery, a pair with each one a mirror image of the other are applied around the fetal head. Each of a pair consists basically of a blade, shank, and a handle (see figure 1 below).

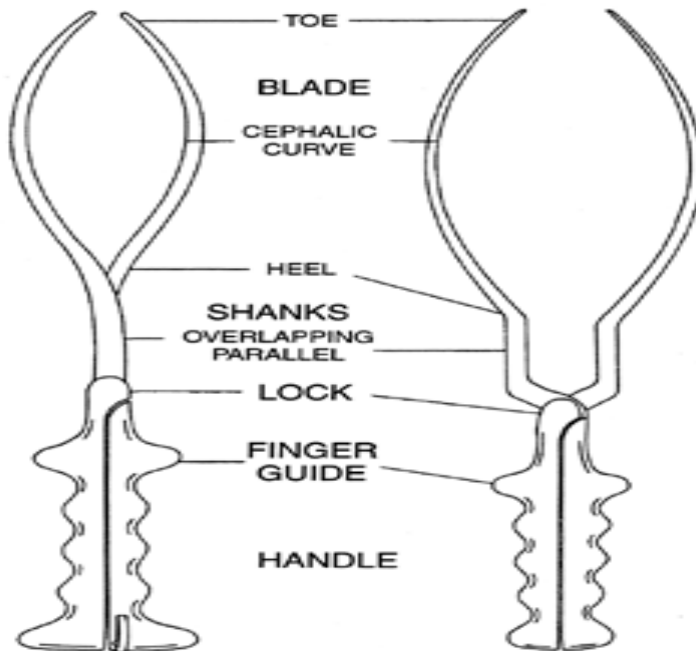


Fig. 1. Parts of the two main types of obstetrical forceps

Based on ability to rotate the fetal head in the birth canal, forceps could be classified into those that can effect traction only and those that can be used to effect rotation and traction. The main difference in the design is in the blades and the lock. An archetype of traction only forceps is the Simpson's forceps with an 'English' lock and pelvic and cephalic curves on the blade while Kielland's forceps is the archetype of traction and rotation forceps with only the cephalic curve and sliding lock (Chiswick and James, 1979).

3. The vacuum extractor

The principle of the vacuum was first applied for the treatment of depressed skull fractures in infants in 1632! That force generated in a closed space (vacuum) can be increased to aid the delivery of a fetus was first reported by James Young, surgeon to the Naval Hospital in Plymouth, England in 1655 (Malmstrom, 1957). About 100 years later Seaman of Jena described his dream of the use of a vacuum device to assist delivery without injury to the mother or baby. “...an air pump which wherewith one can seize the head of the infant without injury to mother and child. The pump was made of brass and had a covering of rubber with ventilators...”. The European medical and lay literature is replete with such fancies, designs and attempts but none drew international attention and widespread acceptance (Vacca, 2003). Malmstrom’s device eventually received international acceptance in the middle of the 20 century. He first introduced his device in 1953 and refined it further by 1957; it was originally used in the first stage of labour to improve uterine action by ‘pulling the head down to the cervix’. Malmstrom is therefore credited as the father of the modern vacuum extractor. The unique feature of the Malmstrom’s Vacuum Extractor is that the metal cup has an in-curved rounded margin which is of a narrower diameter than the base (see figure 2 below). This design produces a chignon on the fetal scalp thereby minimizing the risk of detachment during traction. Other components include a vacuum pump, a gauge, vacuum container and rubber tubing. Malmstrom’s device has been modified by other inventors as extensively discussed in the history of vacuum extraction by Baskett (Vacca, 2003).

Bird significantly modified the cup such that the suction port and the traction port are separated; the suction port located close to the rim of the convex surface of the cup and the traction port located at its center. This helps to reduce the leverage on the cup during traction and reduces the risk of detachment. A further advantage of this modification is the improved accessibility to the flexion point in deflexed occipito-transverse and occipito-posterior positions. The Bird modification is also referred to as the ‘OP’ cup. Over the next 20 years several modifications of the vacuum extractor became popular in Scandinavia, Europe and Africa. This may have been due to a commonly held perception that it required less training for safe use compared to the alternative-obstetric forceps. This view was first suggested about 150 years earlier by Neil Arnott (Vacca, 2003).

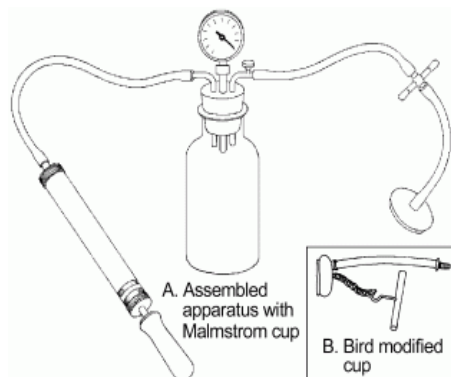


Fig. 2. A Malmstrom's vacuum extractor with its essential components. Inset: Bird's modification of metal cup

4. Types of equipment

4.1 Forceps

Obstetric forceps can be classified based on the depth of the pelvic cavity in which they can be applied to effect delivery (low/outlet, midcavity or high forceps). Worldwide low cavity and outlet forceps delivery are the mostly frequently performed in current practice. High and mid-cavity forceps delivery which could involve rotation of the fetal head are rarely performed. At the Ahmadu Bello University Teaching Hospital, only outlet forceps are performed with low-cavity forceps used occasionally (Adaji et al., 2009).

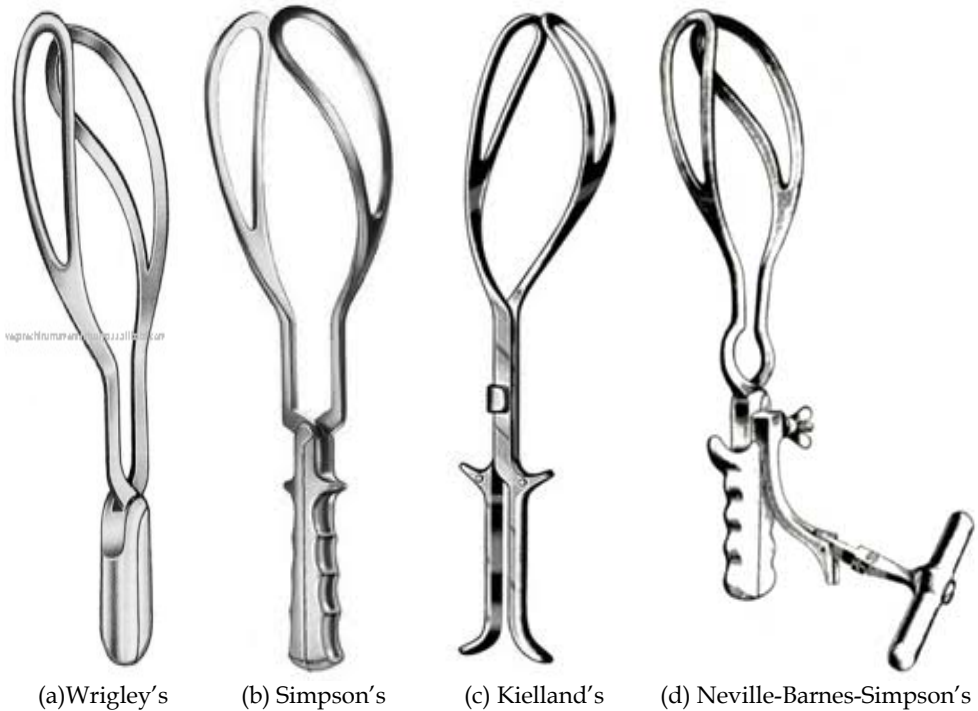


Fig. 3. The common types of obstetric forceps

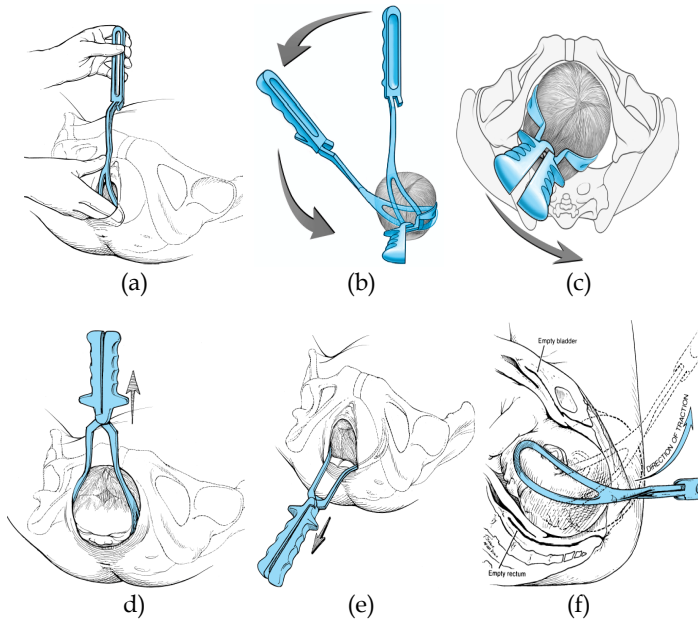


Fig. 4. (a-f) – Application and traction on the fetal head using forceps

4.2 Vacuum extractor

There are different types of vacuum extractors, depending on the type of suction mechanism (manual or electrical) and type of cup-rigid or soft (Silc, Malmstrom, Bird, or the OmniCup). The manual suction mechanism which is suitable for resource poor settings due to frequent power outages may be operated via a foot pump, a hand held “bicycle like” pump both operated by an assistant or a hand held pump operated by the birth attendant (Figure 2). The most common and widely available in resource poor settings is the Malmstrom vacuum extractor with rigid or soft cups.

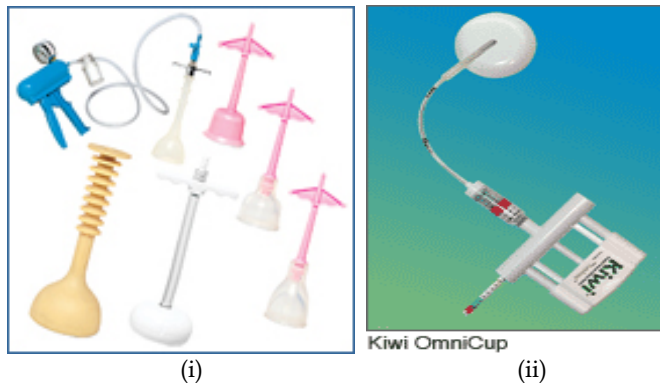


Fig. 5. Vacuum extractor soft cups (i) and the Kiwi Omnicup (ii) which has a rigid plastic cup

A more recent design for the vacuum extractor is the rigid plastic cup Kiwi® vacuum assisted fetal delivery device (Clinical Innovations, Murray, UT). It is designed as an integrated unit for complete control without an assistant. The suction for this device is provided by a PalmPump™. The Kiwi has two versions; the ProCup® for low outlet delivery occipito-posterior positions and the OmniCup® for low occipito-posterior and lateral fetal malpositions. The OmniCup® has a disposable and a recently developed reusable version suitable for resource poor settings. The cost, portability and ease of maintenance of the reusable OmniCup® makes it attractive for use in resource poor settings. The disposable version on the other hand reduces the potential risk of viral infections between patients (Ismail et al., 2008a).

Metal cups appear to be more suitable for 'occipito-posterior', transverse and difficult 'occipito-anterior' position deliveries because they allow a greater traction force to be applied without cup slip offs. The soft cups seem to be appropriate for straightforward deliveries (Johanson and Menon, 2007).

Several studies have evaluated the effectiveness of the OmniCup compared to the standard vacuum extraction equipment (Malstrom metal rigid cup or Silc cups). Two randomized controlled trials found a higher failure rate: 43% vs. 21% (OR = 1.9; 95%CI = 1.01 - 1.36) (Attilakos et al., 2006) and 30%-19.2%, (RR 1.58; 95% CI = 1.10-2.224) with the OmniCup and one RCT found it to be a suitable alternative to the standard cups (100% delivery rate in both groups) (Ismail et al., 2008b). There was no difference in maternal morbidity between both groups in all 3 RCTs. Only one of the RCTs reported a significant increase in neonatal admission for sub-aponeurotic hemorrhage ($p = 0.015$, OR = 0.11; 95CI = 0.001 - 0.87).

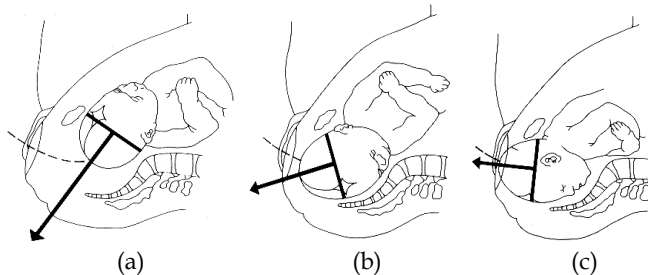


Fig. 6. (a-c) – Position of cup and direction of traction with vacuum extractor

Several observational studies also reported higher rates of successful vaginal delivery which was not statistically different from that for the standard equipment (Ismail et al., 2008a, Hayman et al., 2002, Baskett et al., 2008). Successful vaginal delivery was attributed to familiarity with the equipment. There was also no difference in maternal morbidity in all of these studies. However, Hayman, Gilby and Arulkumaran (2002) reported a significant increase in superficial scalp abrasions in the OmniCup group compared to the standard cup group (Hayman et al., 2002).

The experience from many centers is that nulliparous women with untested pelvis are more likely to need assistance with an operative vaginal delivery procedure. In the Zaria study, more than three-quarters of the parturients who were assisted were nulliparas (Adaji et al., 2009).

5. Epidemiology

Operative vaginal delivery prevalence rates vary from country from country and facility to facility. The rates have however remained fairly stable over the past 3 decades. A recent survey by the World Health Organization (WHO) of method of delivery and pregnancy outcomes in 9 Asian countries analyzed 107, 950 births. Of these births, 3.2 percent were by operative vaginal delivery procedures (Lumbiganon et al., 2010).

Demissie et al comprehensively reviewed operative vaginal delivery rates in US hospitals between 1995 and 1998. Obstetrical forceps were utilized to conduct deliveries in 4.4% of births in 1995, 4% in 1996, 3.6% in 1997 and 3.2% in 1998. The use of ventouse was 7.4%, 7.8%, 7.8% and 7.6% over the same period (Demissie et al., 2004). In the UK, a operative vaginal delivery rates (forceps and ventouse) of between 10 to 15% percent has been estimated (Johanson and Jones, 1999).

Due to weak health systems, national figures for instrumental vaginal deliveries are either unavailable or incomplete from developing countries. Reports from comprehensive emergency obstetric health care facilities may provide the most reliable source of information in such settings. For example, a 5 year review of births at the Ahmadu Bello University Teaching Hospital, Zaria revealed that of 6662 vaginal births between 1997 and 2001, 3.9% were by operative vaginal delivery procedures. Forceps delivery rate was 2.2% while vacuum delivery rate was 1.5%. In addition, fetal destructive operation to deliver confirmed intrauterine fetal deaths was employed in 0.1% of cases (Adaji et al., 2009). This procedure is rarely reported in literature from developed countries suggesting that they are no longer performed. However, in developing countries where moribund mothers, neglected obstructed labour and intrauterine fetal deaths are still seen, fetal destructive operation remains an option [Moody & Maharaj 2002]. Table 1 below shows the situation of operative vaginal procedures based on hospital-based studies in selected countries.

Country	No of births	Year of births	Vacuum (%)	Forceps (%)	All
USA	4,316,233	2007	3.5	0.8	4.3%
England	515,214	2004	7	3	10%
Canada	333,974	2005	10.3	4.6	14.9%
Australia	289,946	2007	7.5	3.6	11.1%
Ireland	71,963	2007	12.3	3.7	16%

Table 1. Operative vaginal deliveries in 5 countries(Gei and Pacheco, 2011)

Assisted vaginal delivery is one of the underutilized and least available emergency obstetric care signal functions in resource poor countries (Kongnyuy et al., 2008, Tsu and Coffe, 2009). Unmet training needs, lack of suitable equipment and human resource shortages are some reasons for this (Bailey, 2005, Fauveau, 2006, Hillier and Johanson, 1994). In many resource poor settings vacuum extraction is performed only by medical doctors who may only be regularly available in large urban hospitals (Fauveau, 2006).

6. Types and classification of operative vaginal delivery procedures

Forceps and vacuum delivery are the most common procedures employed for assisted vaginal delivery. Others like symphysiotomy and fetal destructive operations are rarely if ever performed in developed countries. The ACOG developed a classification system that takes into account the station and position of the fetal head in the maternal pelvis (ACOG, 1992). (Figure 3 and Table 2)

Term	Definition
Outlet	Fetal scalp visible without separating the labia Fetal skull has reached the pelvic floor Sagittal suture is in the antero-posterior diameter or right or left occiput anterior or posterior position (rotation does not exceed 45 degrees) Fetal head is at or on the perineum
Low	Leading point of the skull (not caput) is at station plus 2 cm or more and not on the pelvic floor Two subdivisions: (a) rotation of 45 degrees or less (b) rotation more than 45 degrees
Mid cavity	Fetal head is 1/5 palpable per abdomen Leading point of the skull is above station plus 2 cm but not above the ischial spines Two subdivisions (a) rotation of 45 degrees or less (b) rotation more than 45 degrees
High	Not included in classification

Table 2. Classification for operative vaginal deliveries adapted from ACOG

7. Guidelines and indications

The invention of obstetrical forceps may have been driven by the search for a way to address one of the tragic outcomes of pregnancy of those days; prolonged obstructed labor with a dead fetus. With no luxury of ability to perform a caesarean section, the dilemma faced by the birth accoucheur was undoubtedly formidable. As the tools of the trade grew in number and design, the indications also multiplied. Some institutions like the Royal College of Obstetricians and Gynaecologists (RCOG) UK, The American Congress of Obstetricians and Gynaecologists and the Society of Obstetricians and Gynaecologists of Canada have helped to clearly define the indications for operative vaginal delivery (Table 3). There are several indications for assisted vaginal delivery; these could be due to fetal compromise, maternal indications to avoid Valsalva or inadequate progress in labour. No indication is absolute and each case should be considered individually.

Type	Indication
Fetal	Presumed fetal compromise
Maternal	Medical indications to avoid Valsalva (e.g. cardiac disease Class III or IV*, hypertensive crises, cerebral vascular disease, particularly uncorrected vascular malformations, myasthenia gravis, spinal cord injury)
Inadequate progress	Nulliparous women: Lack of continuing progress for three hours (total of active and passive second stage labour) with regional anaesthesia, or two hours without regional anaesthesia Multiparous women: Lack of continuing progress for two hours (total of active and passive second stage labour) with regional anaesthesia, or one hour without regional anaesthesia

*New York Heart Association classification

Table 3. Indications for operative vaginal delivery (no indication is absolute and each case should be considered individually)

The safe use of both the vacuum extractor and obstetric forceps require prerequisites one of which is that “the operator must have the knowledge, experience and skills necessary to use the instrument” (ACOG, 1994). A list of the essential pre-requisites for operative vaginal delivery is presented in Table 4.

Preparation	Essential
Full abdominal and vaginal examination	Head is $\leq 1/5$ palpable per abdomen Vertex presentation Cervix is fully dilated and the membranes ruptured Exact position of the head can be determined so proper placement of the instrument can be achieved Pelvis is deemed adequate
Mother	Informed consent must be obtained and clear explanation given Appropriate analgesia is in place, for mid-cavity rotational deliveries this will usually be a regional block A pudendal block may be appropriate, particularly in the context of urgent delivery Maternal bladder has been emptied recently Indwelling catheter should be removed or balloon deflated Aseptic techniques
Staff	Operator must have the knowledge, experience and skills necessary to use the instruments Adequate facilities and back-up personnel are available Back-up plan in place in case of failure to deliver Anticipation of complications that may arise (e.g. shoulder dystocia, postpartum haemorrhage) Personnel present who are trained in neonatal resuscitation

Table 4. Prerequisites for operative vaginal delivery

Facility-based studies from several countries show that indications for operative vaginal delivery procedure fall easily within these categories. Indications for vacuum and forceps delivery in 3 large hospitals in 3 countries are shown in table 5 below.

	Vacuum	Forceps
Nigeria (Zaria)		
Delayed 2nd stage of labour	61 (61)	61 (41.9)
Maternal distress	10 (16.4)	18 (12.3)
Medical illness; PET/eclampsia	20 (32.8)	51 (34.9)
Fetal compromise	9 (9)	12 (8.2)
Fetal prematurity	0 (0)	3 (2.1)
Obstructed labour	0 (0)	1 (0.6)
Total	100 (100)	146 (100)
Cameroon (Yaounde)		
Prolonged 2 nd stage	26 (50)	12 (37.5)
Excessive fetal weight	14 (26.9)	10 (31.3)
Acute fetal distress	11 (21.1)	10 (31.3)
Mother with cardiomyopathy	1 (1.9)	0 (0.0)
Total	52 (100)	32 (100)
Greece (Thessaloniki)		
Prolonged 2 nd stage	69 (21.5)	9 (18)
Maternal exhaustion	161 (49)	22 (44)
Non re-assuring fetal status	83 (26)	16 (32)
Others	11 (3.5)	3 (6)
Total	324 (100)	50 (100)

Table 5. Indications for vacuum and forceps delivery in health care facilities

7.1 Other indications

- After coming head of a breech presentation. Piper forceps is used to maintain the fetal head in flexion and also enables traction on the fetal head. It has unique features of having only a pelvic curve but no cephalic curve.
- During caesarean section a Kiwi vacuum extractor or Wrigley's obstetric forceps can be used to deliver a 'floating' fetal head.
- Some obstetricians have also used a single forcep blade as an elevator during difficult delivery of an impacted fetal head.

7.2 Contraindications

The following are contraindications to the performance of operative vaginal deliveries.

- Abnormal fetal lie; transverse and oblique
- Abnormal presentation; breech, face or brow presentation, shoulder
- Unengaged vertex

- Incompletely dilated cervix; Forceps (vacuum extractor deliveries at cervical dilatations of 8 and above have been found to be a viable alternative to caesarean section)
- Clinical evidence of CPD
- Gestational age < 34 weeks gestation: vacuum extraction is contraindicated because of the susceptibility of the preterm infant to cephalhaematoma, intracranial haemorrhage, subgaleal haemorrhage, and neonatal jaundice. Some have even suggested that vacuum extractors should not be used at gestations of less than 36 weeks because of the risk of subgaleal and intracranial haemorrhage.
- Need for device rotation (*vacuum*)
- Deflexed attitude of fetal head
- Fetal conditions (e.g. thrombocytopenia)
- Fetal bleeding disorders (e.g., alloimmune thrombocytopenia) or a predisposition to fracture (e.g., osteogenesis imperfecta) are relative contraindications to operative vaginal delivery. However, there may be considerable fetal risk if the head has to be delivered abdominally from deep in the pelvis.

Blood-borne viral infections of the mother e.g HIV are not a contraindication to operative vaginal delivery. However, it is sensible to avoid difficult operative delivery where there is an increased chance of fetal abrasion or scalp trauma and to avoid fetal scalp clips or blood sampling during labour.

8. Complications

While the role of operative vaginal deliveries using instruments like forceps and vacuum extractor has received wide acclaim, complications, sometimes of profound severity have been documented for both mother and child. These undesired outcomes have made operative vaginal delivery an object of great scrutiny by the medical and lay press.

Complication	Vacuum	Forceps
<i>Maternal</i>		
Genital tract laceration	8 (42.1)	16 (44.4)
Postpartum haemorrhage	0 (0)	7 (19.4)
<i>Fetal</i>		
Skin bruises	0 (0)	10 (27.8)
Neonatal jaundice	3 (15.8)	0 (0)
Cephalo haematoma	4 (21.1)	2 (5.6)
Erb's palsy	0 (0)	1 (2.8)
Fetal death	4 (21.1)	0 (0)
Total	20	36

Table 6. Complications observed with instrumental/operative vaginal deliveries in Zaria Nigeria

While a diverse number of complications have been ascribed to these procedures causality has been difficult to establish.

In the Zaria study, maternal/ fetal complication was found in 22.3% of cases of instrumental delivery. Table 6 above provides details of these complications. The most severe of the complications were the fetal deaths recorded for vacuum deliveries. However the deaths may have been due to the severity of the fetal distress that indicated the procedure rather than the procedure itself.

Newborn intracranial injuries and shoulder dystocia were other complications associated with operative vaginal deliveries from large reviews. Intracranial injuries documented include epidural, subdural and subarachnoid haemorrhages. The fetus could also develop sub-galeal (subaponeurotic) haemorrhage (Doumouchtsis).

9. Symphysiotomy

Cutting a parturient's symphysis pubis allows the two halves of her pelvis to separate up to 2.5 cm permitting an otherwise difficult labour to progress and allowing an assisted or spontaneous birth. The procedure is performed by cutting through the fibro-cartilage of the symphysis pubis and the supportive ligaments with a scalpel while ensuring asepsis. At its introduction, symphysiotomy was reputed to play a key role in providing an alternative mode of delivery for mild to moderate cephalo-pelvic disproportion thereby reducing caesarean delivery rates. Cynics however doubt this and worry about the risks to the pelvic bones and the nearby lower urinary tract structures. As a result, this procedure has fallen out of favour and rarely employed in obstetric practice even in least resource parts of the world. In the Zaria study, no single symphysiotomy was performed in 5 years despite the existence of indications for the procedure (Adaji et al., 2009). Moreover the skill to perform the procedure has dwindled among obstetricians over time. However, some still argue for a role for this procedure because it meets women's socio-cultural expectation of a vaginal delivery in areas with dislike and apathy for caesarean sections (Maharaj and Moodley, 2002)

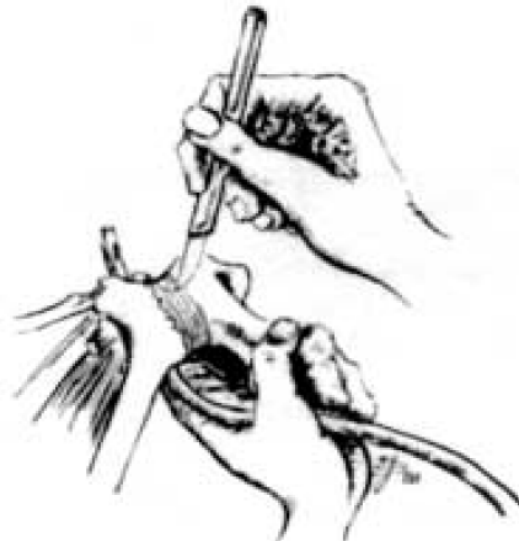

Fig. 7. Performing a symphysiotomy with an instrument placed to protect the urethra

9.1 Fetal destructive operations

These refer to procedures to deliver a dead fetus in the presence of obstructed labour. The value of a caesarean section in this circumstance is low and the maternal situation may even make any resort to an abdominal operation rather dangerous. Craniotomy could be performed to reduce the diameter of the fetal head to allow vaginal delivery, and transverse lie could be relieved by decapitation. Cleidotomy could be performed sometimes to reduce bisacromial diameter when the shoulders of a dead fetus are impacted while evisceration or embryotomy could be performed if the dead fetus is large and or the abdomen is swollen due to an intra-abdominal tumor. Destructive operations are no longer performed in developed countries where the indications for it no longer exists. Even in developing countries most obstetricians shy away from performing the procedure. In Zaria, only 0.1% of deliveries were by destructive procedures (Adaji et al., 2009).

10. Conclusion

Operative vaginal procedures, mainly vacuum extraction and obstetric forceps delivery have a long history but both still have a place in contemporary obstetric practice. In competent hands and with strict adherence to guidelines, the outcomes for the mother and child are excellent. There is great gain in ensuring that these arts are not lost to the modern day obstetrician. On the other hand, procedures like symphysiotomy and destructive operations may still have value in obstetric practice in low income settings. However the evidence for their value need to be laid out clearly and the guidelines for their use comprehensively updated.

11. References

- ACOG (1992) Operative vaginal delivery. ACOG Technical Bulletin. Number 152--February 1991. *Int J Gynaecol Obstet*, 38, 55-60.
- ACOG (1994) Operative vaginal delivery. ACOG Technical Bulletin Number 196-- August 1994 (replaces No. 152, February 1991). *Int J Gynaecol Obstet*, 47, 179-85.
- Adaji, S. E., Shittu, S. O. & Sule, S. T. (2009) Operative vaginal deliveries in Zaria, Nigeria. *Ann Afr Med*, 8, 95-9.
- Ameh, C. A. & Weeks, A. D. (2009) The role of instrumental vaginal delivery in low resource settings. *BJOG*, 116 Suppl 1, 22-5.
- Attilakos, G., Sibanda, T., Winter, C., Johnson, N. & Draycott, T. (2006) A randomised trial of a new handheld vacuum extraction device. *BJOG: An International Journal of Obstetrics and Gynaecology*, 113, 494-495.
- Bailey, P. E. (2005) The disappearing art of instrumental delivery: Time to reverse the trend. *International Journal of Gynecology and Obstetrics*, 91, 89-96.
- Baskett, T. F., Fanning, C. A. & Young, D. C. (2008) A prospective observational study of 1000 vacuum assisted deliveries with the OmniCup Device. *J Obstet Gynaecol Can*, 573 580.
- Chiswick, M. L. & James, D. K. (1979) Kielland's forceps: association with neonatal morbidity and mortality. *BMJ*, 1, 7-9.

- Demissie, K., Rhoads, G. G., Smulian, J. C., Balasubramanian, B. A., Gandhi, K., Joseph, K. S. & Kramer, M. (2004) Operative vaginal delivery and neonatal and infant adverse outcomes: population based retrospective analysis. *BMJ*, 329, 24-9.
- Dunn, P. M. (1999) The Chamberlen family (1560-1728) and obstetric forceps. *Arch Dis Child Fetal Neonatal Ed*, 81, F232-4.
- Fauveau, V. (2006) Is vacuum extraction still known, taught and practiced? A worldwide KAP survey. *International Journal of Gynecology and Obstetrics*, 94, 185-189.
- Gei, A. F. & Pacheco, L. D. (2011) Operative vaginal deliveries: practical aspects. *Obstet Gynecol Clin North Am*, 38, 323-49, xi.
- Hayman, R., Gilby, J. & Arulkumaran, S. (2002) Clinical evaluation of a "Hand Pump" vacuum delivery device. *Obstet Gynecol*, 100, 1190-1195.
- Hillier, C. E. M. & Johanson, R. B. (1994) Worldwide survey of assisted vaginal delivery. *International Journal of Gynecology and Obstetrics*, 47, 109-114.
- Ismail, N. A. M., Saharan, W. S. L., Zaleha, M. A., Jaafar, R., Muhammad, J. A. & Razi, Z. R. M. (2008a) Kiwi Omnicup versus Malmstrom metal cup in vacuum assisted delivery: A randomized comparative trial. *J Obstet Gynaecol Res*, 34, 350-353.
- Ismail, N. A. M., Saharan, W. S. L., Zaleha, M. A., Jaafar, R., Muhammad, J. A. & Razi, Z. R. M. (2008b) Kiwi Omnicup versus Malmstrom metal cup in vacuum assisted delivery: A randomized comparative trial. *J Obstet Gynaecol Res.*, 34, 350-353.
- Johanson, R. & Jones, P. (1999) Operative vaginal delivery rates in the United Kingdom. *J Obstet Gynaecol*, 19, 602-3.
- Johanson, R. B. & Menon, B. K. (2007) Vacuum extraction versus forceps for assisted vaginal delivery (Review). *The Cochrane Collaboration*. John Wiley & Sons, Ltd.
- Kongnyuy, E. J., Leigh, B. & Vandenbroek, N. (2008) Effect of audit and feedback on the availability, utilisation and quality of emergency obstetric care in three districts in Malawi. *Women and Birth*, 21, 149-155.
- Lumbiganon, P., Laopaiboon, M., Gulmezoglu, A. M., Souza, J. P., Taneepanichskul, S., Ruyan, P., Attygalle, D. E., Shrestha, N., Mori, R., Nguyen, D. H., Hoang, T. B., Rathavy, T., Chuyun, K., Cheang, K., Festin, M., Udomprasertgul, V., Germar, M. J., Yanqiu, G., Roy, M., Carroli, G., Ba-Thike, K., Filatova, E. & Villar, J. (2010) Method of delivery and pregnancy outcomes in Asia: the WHO global survey on maternal and perinatal health 2007-08. *Lancet*, 375, 490-9.
- Maharaj, D. & Moodley, J. (2002) Symphysiotomy and fetal destructive operations. *Best Pract Res Clin Obstet Gynaecol*, 16, 117-31.
- Malmstrom, T. (1957) The vacuum extractor, an obstetrical instrument. *Acta Obstetrica at Gynecologica Scandinavica*, 6, 5-50.
- Tsu, V. D. & Coffe, P. S. (2009) New and underutilised technologies to reduce maternal mortality and morbidity: What progress have we made since Bellagio 2003? *BJOG: An International Journal of Obstetrics and Gynaecology*, 116, 247-256.
- Vacca, A. (2003) Handbook of vacuum delivery in obstetric practice. Australia, Vacca Research.